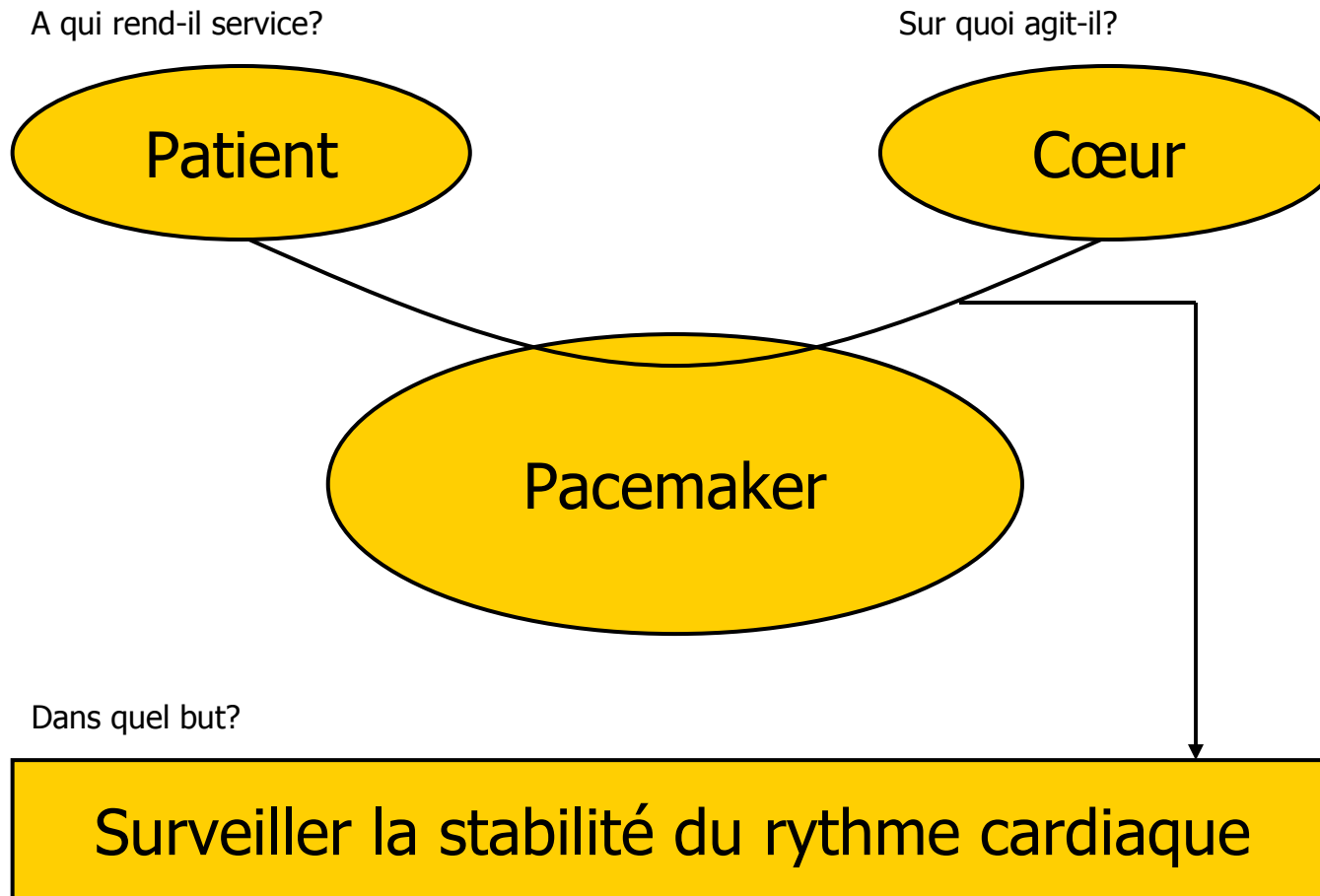


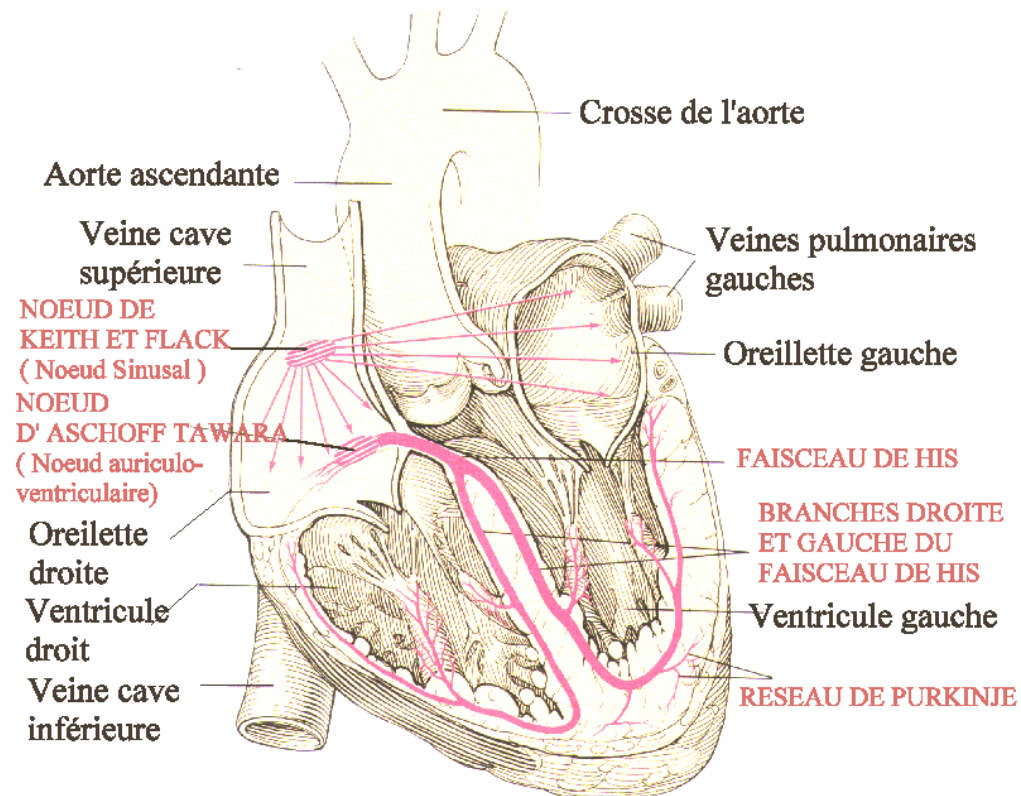
I.


# Présentation



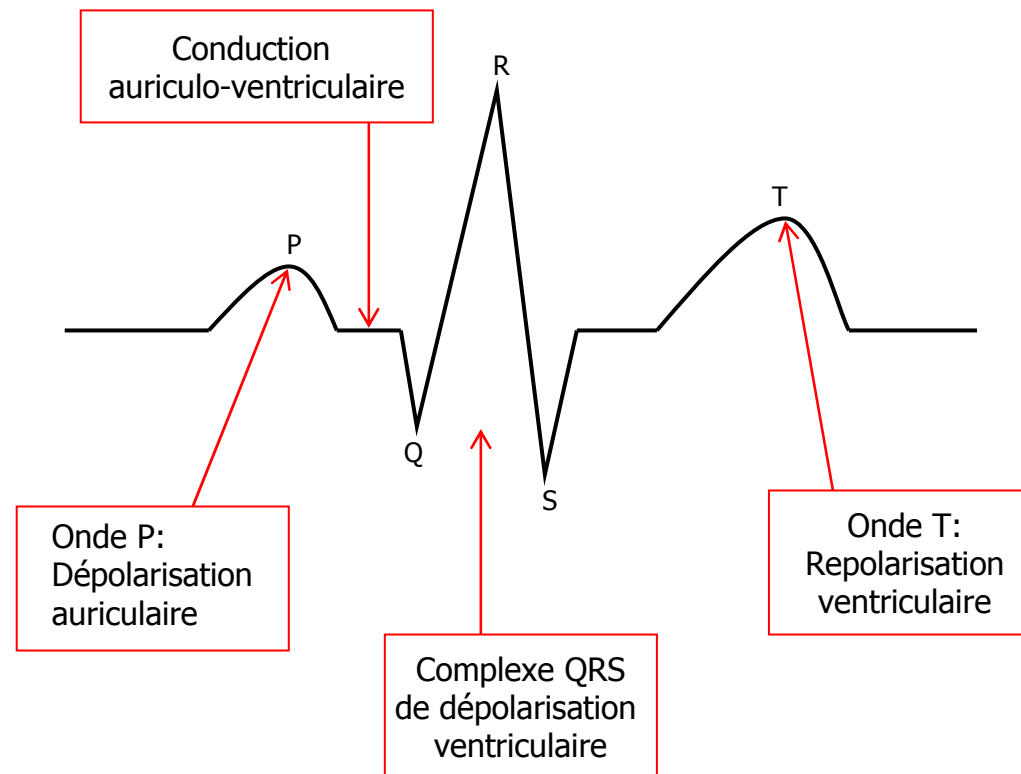
## II.


# Anatomie du cœur





# Electrocardiogramme (ECG)





# Plan

---

## I. Anatomie du cœur

- ❖ Fonctionnement général
- ❖ Conduction de l'influx nerveux

# Anomalies rythmiques

